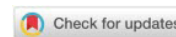


DIFFICULTIES IN RECOVERING THE ELBOW JOINT AFTER INJURIES

Ana Nikolova^{1*}

¹Trakia University, Medical College - Stara Zagora, Bulgaria, e-mail: ana.nikolova@trakia-uni.bg



Abstract: The unique qualities of the elbow joint as a result of its specific function in the upper extremity make it well studied. The elbow functions by employing the concerted activity of its musculotendinous and bony structures. The shoulder determines the special position of the limb, whereas the elbow regulates the limb length and height to optimize the hand position and function. The evaluation of an elbow injury depends on the correlating symptoms and the history with a careful physical and radiographic examination. The high degree of congruity of the articular surfaces and the relatively small capsular volume makes the elbow joint very complicated. Any significant distortion of the normal anatomy, including bony deformity (congenital post-traumatic), bony or fibrous ankylosis and in some cases, prior surgery (ulnar nerve transposition) plays a major role in its functional recovery. It is often impossible to identify the exact etiologic abnormality responsible for the elbow stiffness and pain. This is one of the most frustrating aspects of treating patients with elbow trauma. There are many theoretic explanations of the possible etiologies, responsible for the common types of elbow joint complications, concerning the anatomic structure, physiologic abnormality or biomechanical alteration responsible for the problems of reaching full range of motion.

Keywords: *Osteophytes, Contractures, Compensatory movements*

Introductions

Fractures in the elbow joint area are common and usually lead to impairment of its normal function. They are some of the most difficult upper extremity injuries to treat surgically and with kinesiotherapy. Elbow stiffness is a common complication after trauma (Dai et al., 2020). Restriction of movement can lead to a significant reduction in work capacity, a change of occupation and difficulty with a number of activities of daily living. Of all the fractures, 7% were ulnar fractures, with 1/3 of them affecting the distal humerus, 33% affecting the capitellum and neck of the radius, 20% the olecranon, and the rest being Monteggia fracture and those of the coronoid process.

The treatment of elbow stiffness is difficult and the sequel is still not ideal (Qian et al, 2020).

There is controversy regarding the most accurate method of treatment and model of elbow joint repair due to the fact that it is extremely sensitive to immobilization and quickly becomes rigid. In contrast to the shoulder, in the elbow joint even the smallest inconsistencies in the articular surfaces lead to loss of movement, and prolonged immobilization - to contractures of the joint.

Discussion

Osteophytes

First, we must pay attention to the progress of ectopic ossifications as an issue and main obstacle for functional results. Morrey and Harter announce that the growth of pathological formations in the elbow joints under different forms includes heterotrophic ossifications, myositis ossification and peri-articular ossifications (Morrey & Harter, 2009). Heterotopic ossification refers to the formation of pathologic bone in nonosseous tissues (Yang et al, 2020). The heterotrophic ossifications are considered a formation of mature plastic bone in the soft tissue. The myositis ossification is considered a result of abnormal formations from the bone to inflamed muscles. The calcifications in the elbow are apparently different from the ossifications. Typically, the calcifications consist of calcium pyrophosphate and don't contain mature tissue, having mostly a tubular structure. The calcification is located on the tendons, the synovial, the joint capsule and the ligaments. Calcium accumulation is quite common with the ligaments after a significant injury or elbow fracture. Thomson and Garcia document ectopic bone formations in more than 1,200 patients after elbow fractures, 3% with normal dislocation, 20% with dislocation followed by a fracture of the radial head and 16% with dislocation in a combination with other fractures around the elbow (Thomson & Garcia, 1967). According to the authors there isn't a precise definition of what causes the ectopic ossifications and that's why they refer to these three types of injuries.

*Corresponding author: ana.nikolova@trakia-uni.bg



The soft tissue components (m. Brachialis) in trauma are closely connected with the appearance of ectopic ossifications Frassica and Kundel reports about the high frequency of ossification of 49% and he explains it with the duration of the operation (Morrey, Sotelo & Morrey, 2017; Kundel et al, 1996).

The delay of the surgery is indicated by other authors (Kundel et al, 1996; Wilner, 1948) as a reason for the formation of ectopic ossification, but this has not been proven (Hastings & Graham, 1994).

While many studies have investigated HO formation after open elbow surgery, there are few case reports describing the HO formation after arthroscopic elbow surgery (Desai, Ramalingam & Ruch, 2017).

In these studies, HO formation after elbow arthroscopy was reported to be uncommon (Yang et al 2020).

It is widely known that in some cases the ossifying myositis is a result of incorrect physiotherapy. Cyriax proves that the reason is the primary injury (Cyriax, 1936).

Primary risk factors for developing ectopic ossification:

- Elbow trauma
- Open elbow fracture with dislocation and debridement
- Elbow dislocation with fracture and open reduction and internal fixation (ORIF)
- Radial head fracture and surgery delay of more than 24 hours after the injury
- Unsuccessful ORIF and revision after approximately 3 months
- Rupture of the distal biceps muscle tendon
- Repeated inappropriate physiotherapy treatment in the first 2 weeks
- Patients with severe trauma of the central nervous system

Postoperative complications and risk factors:

- Debricolage
- Peripheral nerve damage
- Severe contractures
- Aseptic necrosis
- Post traumatic arthritis
- Infection
- Avascular necrosis
- Joint instability after surgery
- Osteoporosis
- Pathological valgus angle

The average value of the normal carrying angle is 11°-14° for men and 13°-16° for women (Morrey, 1993) In case that the valgus angle is changed with up to 20° it doesn't affect the function of the elbow joint and the soft tissue structure, it results only in a cosmetic defect. But in the case of larger changes with more than 20°, there will be both cosmetic defects as well as a negative impact on the elbow joint functions. An incongruence of the elbow joint might be with a better prognostic impact than the changes of the condyle-diaphyseal angle, which doesn't correspond to the incongruence of the elbow joint. The soft tissue trauma has a significant influence on the final functional result. The elbow joint is sensitive to injuries, which cause rupture of the soft tissue and a hematoma (Nirsch, Morrey, 1993). Pain and swelling lead to restriction of the movements and to permanent tissue rigidity. The fat pad located in the fossa olecrani becomes hard and fibrotic which is the main reason for restriction of the elbow extension to the last 10°. The fibrosis and shortening of the collateral ligaments and the joint capsule cause hardening of the joint. The unusual response of the joint capsule to an injury is explained by the proximity of the head of the brachialis muscle, which is tightly fitted to the front of the joint. The brachialis muscle is built by 95 % muscle tissue and a small part - by tension structure (Morrey, An, Chao, 1993). This muscle is directly affected by the injury and is susceptible to fibrosis. The rich blood supply is a potential factor for contracture of the capsule and the brachialis muscle, thus producing a severe contracture by flexion.

Contractures

The contractures in the elbow joint are caused by structural changes in the surrounding tissues, which lose their elasticity. The post traumatic immobilization in the elbow joint is usually is 70°-90° flexion. This position doesn't provoke pain and swelling. In response to the trauma, the joint capsule starts thickening and becomes fibrotic. The joint capsule gets used to the immobilization position which can

lead to issues with the extension at a later stage. Other major reasons for the occurrence of contractures can be swelling, hemarthrosis, necrosis of the capsule-ligament apparatus, arthrosis, ectopic ossification in the joint and the surrounding tissue, followed by calcified formations. A common cause for the limited mobility is the abnormal consolidation of the bones, forming the joint.

The contractures involve flexion and extension. The first ones prevent full flexion, while the latter prevent full extension. The muscle contractures have a neurogenic, protective, and structural nature. The flexors are more prone to be contracted in comparison with the extensors. The more severe the contractions are, the more limited the movement of the upper limb is. From a functional point of view, the flexor contractures are more favorable. With flexion contractures the extension is performed by moving the shoulder forwards along with rotation of the arm outwards with maximum extended fingers. The extension contractures are a compensatory movement in the opposite direction, the shoulder is extended backwards with maximum flexion of the wrist and arm.

Compensatory movements

The joint contractures are related to limited mobility. In our desire to overcome the restriction, we provoke compensatory mechanisms. They don't improve the functional capabilities of the patient. When there is a flexion contracture, the extension is compensated by extending the shoulder forwards along with external rotation of the arm, with maximum extended arm and fingers. In case of extension contractures, it is the other way round. The patients support their supination by ADD along with external rotation in the shoulder joint while for pronation it is by abduction and internal rotation.

The movements in the radio-ulnar joint can be successfully restored. In the daily routines and for self-attendance, the incomplete flexion in the elbow joint is compensated by lifting the shoulder upwards, the head of the humerus forwards while the arm is extending.

When the extension is not sufficient, the body leans forward or the lower limbs are nearer the body so that the object can be brought closer to the limb (putting on socks, shoes, etc.)

The main factor for compensation of the valgus instability is reaching an active direct and indirect stabilization by m.supinator, m.pronator teres and the muscles from the lateral pack (Попов, 2002).

All patients perform compensating movements in the same way, irrespective of their age or physical activity.

The compensatory mechanism are movements that the patients perform as unconscious acts without thinking about them.

Muscle Discoordination in the elbow field

The muscle discoordination is most often a result of compensatory movements. At the same time, the muscles antagonists are activated in the elbow joint, especially with flexion. The simultaneous pulling in both directions makes difficult the movement of the forearm, regardless of the exhausted movement volume. The active muscles in the elbow form a pathological synergy. Simultaneous activity of the flexors in the elbow with those of the wrist and fingers is often observed as well as of the muscle extensors in the elbow with the abductors of the shoulder.

Compensatory function of the muscles

The unaffected muscles are trying to undertake part of the function of the affected muscles. In the adjacent joints, substitution functions can be executed only by two joint muscles. For example, during targeted training for the biceps muscle, it can perform supination in full capacity.

Consequences after immobilization and injuries

The immobilization can be a cause of reduced muscle strength. The flexors are weaker than the extensors, and they may not be able to contract and affect the extensors. In such a case, the elbow joint can be hyperextended during unfolding. The muscle flexors which contribute to the joint compression are getting weaker, practically the joint stabilization is reduced. If the immobilization is worn for a long time in a position of 90 degrees flexion in the elbow joint, it will lead to shortening of the elbow flexors and, on the other side, to elongation of the extensors.

Actually, this is the reason why the volume of movement during extension is limited.

"The pain and the oedema restrict the movements and cause permanent tissue contraction. The located in Fossa olecranii fat pad from soft and movable became fibrotic after the injury. It interferes with extension in the joint " (Енчев, 2009).

“POSITIVE FAT PAD SIGN” is most common in cases of issues with the intra-articular joint (injury of the olecrani, radial head or coracoid process), and with a Monteggia fracture.

The fat pad is located in the back of the deep fossa of the olecranon along the length of the distal humerus between the anconeus and the triceps brachii muscles.

The anterior fat pad is located in the area of the radius and the coronoid. When the upper limb is being extended in the elbow joint, the fat pad takes the form of the brachialis, and when it's being flexed its form changes, depending on the tension of the intra articular structures. Its form depends on its location. During flexion, the shape is determined by the compression of the triceps tendons and the anconeus. The posterior pad possesses larger mobility than the anterior one during extension. Its shape also depends on the compression of the structure in its area (Skaggs & Mirzayan, 1999; Miles & Lamont, 1989).

There are 4 types of FAT PAD SIGN

1. Positive posterior: it appears while the upper limb is moving from 90 degree flexion to extension. The fat pad is moving in supra-posterior direction

2. The false posterior one is seen during extension of the elbow joint in the presence of laxity of the posterior joint capsule and dislocation of the olecranon

3. Paradoxical posterior occurs in external joint processes (neoplasy or haemorrhage in the supracondylar humerus fractures); they can elevate the periosteum and move the proximal part of the fat pad in dorsal direction.

4. Supination FAT PAD SIGN: it appears in fractures of the radial head.

The scientific research on the relation between the FAT PAD SIGN and a bone injury presents announcements that the anterior fat pad is an indication for inter articulation fractures in 70-80% of the cases. On the other side, for the posterior fat pad sign, in 90% of the cases it is probably an inter articulation fracture. If the elbow is not injured, the anterior fat pad can be seen, however, the posterior one can be seen only if there is some injury.

Concerning the problem of recovering the full extension of the elbow joint, we came to the conclusion that the main problem is the posterior fat pad which becomes thickened and hard.

This problem is neglected in the practice, however, it is particularly important for the recovery process. For this reason the flexion limitation is a rare issue. Although it can affect one of the three nerves (n. Medianus, n. Ulnaris, n. Radialis), the most common concern during the injury is n. Ulnaris. (Gonzalez et al, 2001).

The nerve is located near the medial epicondyle, the narrow space in which n. Ulnaris passes, which explains the frequency of the ulnar neuropathy. Usually, the patients report hypersensitivity, pain and paresthesia along the nerve. These complaints may persist for several months. (Spinner, Linsheid, 1993).

Conclusion

Immobilization leads to reduced muscle strength and contractures, and hence to the occurrence of compensatory movements and muscle discoordination in the elbow joint. After elbow joint trauma, the soft and mobile fat pad located in the Fossa olecranii fibroses and blocks the extension of the joint.

Complications can be ectopic ossifications, severe contractures, aseptic necrosis, post-traumatic necrosis, infection, avascular necrosis, osteoporosis, pathologically altered valgus angle, joint instability after surgery, etc. All this leads to restriction of movements and hence to limitation of activities of daily living, inability to perform work and professional activities.

Restoring the function of the elbow joint after a fracture is a complex and lengthy process, which requires a precise selection of the means of kinesitherapy and their exact dosage.

References

Cyriax, J. H.. The pathology and treatment of tennis elbow. *The Journal of Bone & Joint Surgery*: October 1936 - Volume 18 - Issue 4 - p 921-940

Dai, J., Zhang, G., Li, S., Xu, J., & Lu, J. (2020). Arthroscopic treatment of posttraumatic elbow stiffness due to soft tissue problems. *Orthopaedic Surgery*, 12(5), 1464-1470

Desai, M. J., Ramalingam, H., & Ruch, D. S. (2017). Heterotopic ossification after the arthroscopic treatment of lateral epicondylitis. *Hand*, 12(3), NP32-NP36.

Gonzalez, M. H., Lotfi, P., Bendre, A., Mandelbroyt, Y., & Lieska, N. (2001). The ulnar nerve at the elbow and its local branching: an anatomic study. *Journal of hand surgery (Edinburgh, Scotland)*, 26(2), 142–144. <https://doi.org/10.1054/jhsb.2000.0532>

Hastings II, H., & Graham, T. J. (1994). The classification and treatment of heterotopic ossification about the elbow and forearm. *Hand clinics*, 10(3), 417-437.

Kundel K, Braun W, Wieberneit J, Rüter A. (1996) Intraarticular distal humerus fractures. Factors affecting functional outcome. *Clinical Orthopaedics and Related Research*. (332):200-208. PMID: 8913164.

Miles, K. A., & Lamont, A. C. (1989). Ultrasonic demonstration of the elbow fat pads. *Clinical radiology*, 40(6), 602-604.

Morrey, B., An, K. and Chao, E. (1993) Functional Evaluation of the Elbow. In: Morley, B.F., Ed., *The Elbow and Its Disorders*, 2nd Edition, WB Saunders, Philadelphia, 86-97

Morrey BF. (1993) Surgical exposures of the elbow. In Morrey BF.edc. *The elbow and its disorders* second edition. W. B. Saunders Company, p.11-36 Phyladelphia,.

Morrey BF, Harter GD. (2009) Ectopic ossification about the elbow. Chapter 31. *The elbow and its disorders*. 4th ed. Philadelphia: W. B. Saunders;. p. 472.

Morrey, B. F., Sotelo, J. S., & Morrey, M. E. (2017). *Morrey's The Elbow and Its Disorders E-Book*. Elsevier Health Sciences

Nirsch RP, Morrey BF. (1993) "Surgery and rehabilitation", p.115-155, *The elbow and its disorders*, Chapter 7, Saunders;

Qian, Y., Yu, S., Shi, Y., Huang, H., & Fan, C. (2020). Risk factors for the occurrence and progression of posttraumatic elbow stiffness: a case-control study of 688 cases. *Frontiers in Medicine*, 7, 604056.

Skaggs, D. L., & Mirzayan, R. (1999). The posterior fat pad sign in association with occult fracture of the elbow in children. *JBJS*, 81(10), 1429-33.

Spinner M, Linsheid R L, (1993) Nerv entrapment sindroms. In Morrey BF eds *The Elbow and its disorders* 2 ed W>B>Saunders Phyladelpfia; 60: 813-832

Thompson, H. C., 3rd, & Garcia, A. (1967). Myositis ossificans: aftermath of elbow injuries. *Clinical orthopaedics and related research*, 50, 129–134.

Willner P. (1948) Anterior capsulectomy for contractures of the elbow. *J Int Coll Surg*; 11(4):359-62.

Wilson P. (1944) Capsulectomy for the relief of flexion contractures of the elbow following fracture. *J Bone Joint Surg*;26(1):71-86

Yang, C. Q., Hu, J. S., Xu, J. G., & Lu, J. Z. (2020). Heterotopic ossification after arthroscopic elbow release. *Orthopaedic Surgery*, 12(5), 1471-1477

Енчев Д. (2009) „Оперативно лечение на бикондиларните фрактури на хумеруса (тип С)“ ,Дисертационен труд,стр. (75-80), София,

Попов Н. (2002),“Биомеханично състояние и промени в горния крайник след резекция на главата на радиуса“ .Сп.Кинезитерапия, бр.1/, стр.27-33), София.

